Nature Environment and Pollution Technology
An International Quarterly Scientific Journal

p-ISSN: 0972-6268
e-ISSN: 2395-3454

Vol. 16 | No. 3 | pp. 821-828 | 2017

Original Research Paper | Open Access

Gross and Histopathological Study of Ziram Induced Subchronic Toxicity in Broiler Chickens

Majid Shafi†, Shayaib Ahmad Kamil, Masood Saleem Mir, Mohammed Maqbool Darzi, Abdul Shakoor Bhat, Showkat Ahmad Shah and Omer Khalil Baba

Division of Veterinary Pathology, Faculty of Veterinary Sciences and Animal Husbandry, Shuhama, Alusteng, SKUAST- Kashmir, India

†Corresponding author: Majid Shafi

Nat. Env. & Poll. Tech.
Website: www.neptjournal.com

Received: 10-09-2016
Accepted: 19-10-2016

Key Words:
Broiler chickens
Ziram fungicide
Lymphoid tissue

ABSTRACT

The present experimental work was conducted to elucidate the pathological changes in broiler chickens after ziram intoxication. For this study 120 apparently healthy broiler chicks were reared up to 2 weeks of age and allocated randomly to two groups, i.e. sub-chronic toxicity (N=90) and control group (N=30). Toxicity was induced in broiler chicks by giving 1 mg/kg body weight per day for the study period of 90 days in case of sub-chronic intoxication. At the end of the experimental period the investigations revealed depletion of lymphoid tissue from the lymphoid organs which were suggestive of immunosuppressive and immunomodulatory effects of ziram in chicken.

INTRODUCTION

Pesticides are substances or mixture of substances intended for preventing, destroying, repelling or mitigating any pest. There are many groups of pesticides which are commonly used in agriculture. These include algicides, bactericides, insecticides, fungicides, acaricides, molluscicides, nematicides, rodenticides and virucides. Among these, fungicides and insecticides are commonly used in agriculture. Fungicides are chemical compounds or biological organisms used to kill or inhibit fungi or fungal spores. The fungicides which are commonly used in orchards of Jammu and Kashmir State include Capton, Dithionon, Mancozeb, Zineb and Ziram. Ziram is used widely on fruit and nut trees, apples, vegetables and tobacco. The indiscriminate use of fungicides and pesticides on fruit crops has led to the decline of many birds and beneficial insect populations. Insects feeding on the sap of the apple tree or buds die instantly during the spraying of these pesticides. After eating the poisoned insects, the birds become drowsy and are not able to fly (Ajaz 2010). Although there are benefits of the use of pesticides, but on the other hand, toxicity of pesticides to humans, birds and other animals pose a potential threat. Keeping in view the paucity of information regarding the toxicity of the chemical, this study was undertaken to observe pathological changes in broiler chickens.

MATERIALS AND METHODS

A total number of 120 healthy broiler chicks were procured from the market and used for experimental purpose. All the chicks were vaccinated against Marek's disease on the first day of hatching. The chicks were given Furasol @ ½ gram per litre of water for 5 days in the first week of the experiment to prevent coccidiosis in chicks. The chicks were given broiler starter ration for two weeks followed by broiler finisher ration as per the standards. The chicks were reared up to 2 weeks of age. After that the chicks were divided into two groups viz. subchronic toxicity group and control group on random basis. The subchronic group consisted of 90 chicks and the control consists 30 chicks. The control group received fungicide free diet; whereas the subchronic groups received fungicide in the feed.

Induction of toxicity in chicks: For inducing toxicities, the ziram as available in the market was used. The dose rate was selected on the basis of LD_{50} by dividing the number of days in each toxicity group. The LD_{50} of ziram in birds is 100 mg/kg body weight (Michael 1997). For inducing subchronic toxicity, LD_{50} dose was given orally in divided doses daily for 90 days i.e., 1 mg/kg body weight per day.

Histopathological studies: All the sacrificed birds along with those died during the experiment were subjected to detailed postmortem examination. For histopathological

EXPERIMENTAL DESIGN

Sr. No.	Group	Sub Chronic Group	Control Group
1	Dose	1 mg/kg b.wt.	Nil
2	Route	Oral	Nil
3	Number of birds	90	30
4	Day of blood collection	10 days interval	10 days interval
5	Sacrifice of birds	10 days interval	10 days interval
6	No. of birds scarified at once	10 birds	3 birds

studies, pieces of different internal organs were collected in 10% buffered formalin and the tissues were processed routinely and stained with haematoxylin and eosin as recommended by Lilly (1954).

GROSS PATHOLOGICAL CHANGES IN SUB-CHRONIC TOXICITY AND CONTROL GROUPS

The ziram intoxicated birds revealed progressively severe hyper-salivation, dehydration and emaciation. At later stages, loss of breast musculature was evident by prominent, sharp and clearly demarcated gelatinized keel bone. At early stage, liver appeared normal and at later stages it was darker, enlarged, swollen, congested and frequently necrotic areas. At day 60, kidneys were enlarged, congested and mottled with petechial haemorrhages. The lungs revealed varying degrees of congestion and haemorrhages. In birds dead after day 60, lungs were generally emphysematous, haemorrhagic and consolidated. Heart was generally enlarged with pericarditis and pericardial gelatinization. Proventriculus generally appeared enlarged, oedematous and congested with serous exudates in the lumen. Varying degree of haemorrhages was also observed on the mucosal surface. In most of the birds, caecum appeared to be enlarged and distended. Throughout the period of the study, the crop was dilated, gelatinized with the presence of viscous mucinous fluid in the lumen. Spleen generally revealed pinpoint necrotic spots. After day 60, spleen appeared to be atrophied with rough surface. Haemorrhages were frequently noted in bursa of fabricious which was also atrophied from day 70. Thymic lobes appeared to be reduced in size. Slight increase in size of thyroid was noted from day 40. Pancreas appeared soft, oedematous and congested. Thyroid progressively increased in size, which was mostly evident from day 40 onwards.

Control: The birds scarified from the control group did not reveal any significant gross lesion in any of the organs.

Histopathology

Sub-chronic Toxicity

Brain: Varying degrees of congestion involving meningeal vessels, cerebral microvasculature, choroid plexus and cerebellum were noted up to day 30. Progressively severe changes were observed thereafter. At the end of study period, cerebral cortex revealed degeneration, necrosis, satellitosis and neuronophagia (Fig. 1 and Fig. 13).

Lungs: In general, lungs revealed varying degrees of vascular congestion and haemorrhages from day 30 to day 60. Birds succumbing during the period of study frequently revealed emphysema due to rupture of air vesicles. Focal

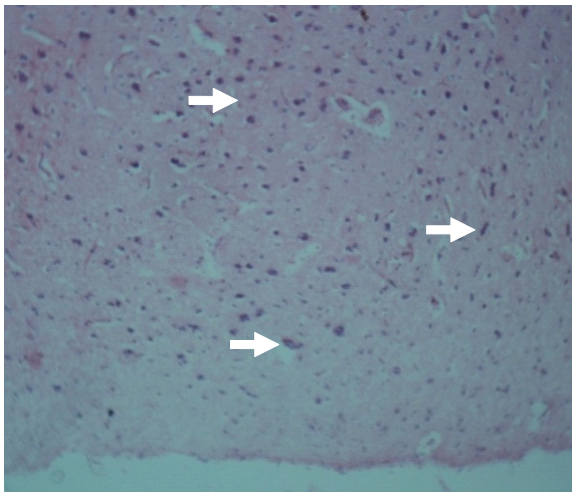

Fig. 1: Photomicrograph of brain showing neuronal degeneration, satellitosis, neuronophagia (arrow) (H & E 10X).

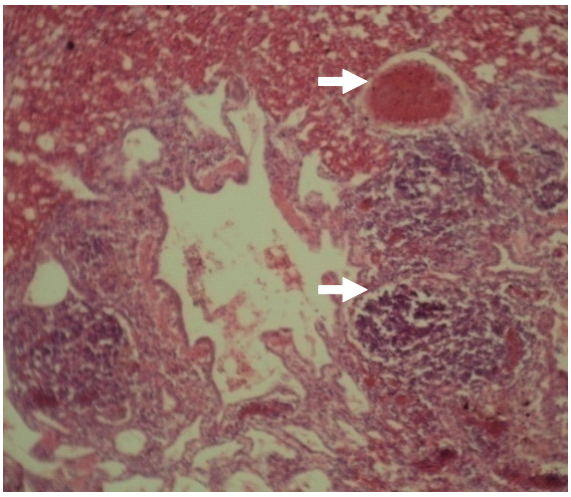

Fig. 2: Photomicrograph of lung showing congestion and bronchopneumonia (arrow) (H & E 10X).

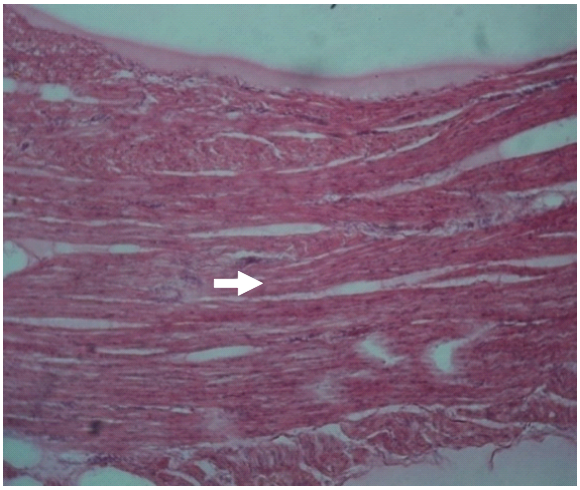

Fig. 3: Photomicrograph of heart showing Zenker's degeneration (arrow) and cellular infiltration (H & E 10X).

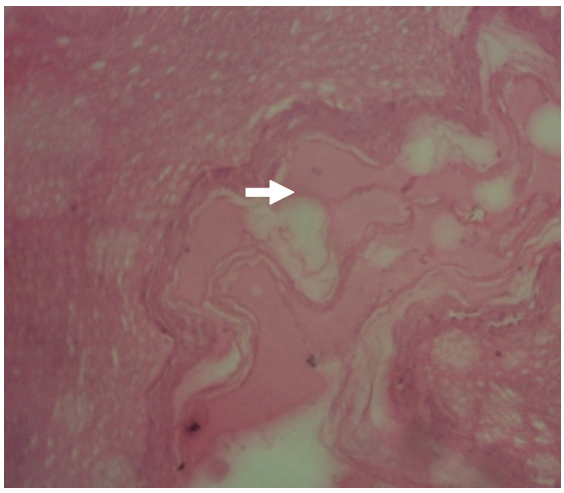

Fig. 4: Photomicrograph of crop showing oedema (arrow) (H & E 10X).

areas of bronchopneumonia were also observed in few birds died or sacrificed from day 70 up to 90 (Fig. 2).

Heart: No changes were evident up to day 20 of intoxication. Thereafter, vascular congestion, focal haemorrhages and varying degrees of degenerative changes of cardiomyocytes were consistently observed. The degenerative changes characterized by cytoplasmic eosinophilia, nuclear pyknosis and nuclear rarefaction. At the end of the experimental period, Zenker's degeneration of heart muscles was evident (Figs. 3).

Crop: The crop revealed varying degrees of degenerative changes and mucosal keratinization of crop. The birds scarified or died after day 40 to day 60 showed oedema of crop (Fig. 4).

Kidneys: Birds scarified at day 10 and 20 revealed mild vascular congestion, haemorrhages and varying degrees of nephritic changes. At days 60 and 70, haemorrhages, glomerular atrophy, tubular degeneration and necrosis were evident. Similar but more severe nephritic changes were observed at day 90 (Figs. 5 and 15).

Liver: Livers from the birds scarified at days 10 and 20 revealed moderate degenerative changes characterized by cellular swelling and focal hepatitis. The birds scarified or died after day 40 to day 60 showed vascular congestion, swelling, dilatation of sinusoids and necrosis. The birds scarified at the day 90 showed severe hepatic congestion, hepatocellular swelling, hyperplasia, thickening of capsules and cytolysis and kuffer cell hyperplasia (Figs. 6 and 14).

Spleen: Congestion and haemorrhages were consistently observed. From day 30 onwards, depletion of periarterolar lymphoid sheath was evident in case of ziram intoxicated birds. Depletion of lymphoid cells was more prominent at the end of the study period (Figs. 7 and 16).

Bursa: No changes, except mild vascular congestion, were noted up to day 20. From day 50 onwards, lysis out of lymphoid cells characterized by the presence of empty spaces were frequently observed. Thereafter, haemorrhages and progressively severe depletion of lymphoid cells were noted towards the end of the study period (Fig. 8).

Thymus: No changes were evident up to day 40. Thereafter, varying degrees of congestion and loss of lymphoid tissue were consistently observed up to the end of the experimental period (Fig. 9). Microscopic examination further revealed atrophy, decrease in size of the follicles and haemorrhages in thymus.

Thyroid: No changes were observed up to day 40. From day 40 onwards thyroid follicles appeared to be hypertrophied and were filled with colloidal material (Fig. 10). Also, desquamation and hyperplasia of glandular epithelium was noted at days 70 and 80. Similar, but more severe changes were observed at day 90.

Proventriculus: Vascular congestion, denudation and oedema of submucosa were a consistent feature from day 30 onwards (Fig. 11). The glandular epithelium revealed degenerative changes with increased mucous production. From day 50 onwards, proventriculus showed hyperplasia of mucosa with heavy infiltration of lymphocytes.

Gizzard: Gizzard revealed moderate degeneration, dilatation of glands and cellular infiltration in ziram intoxicated birds.

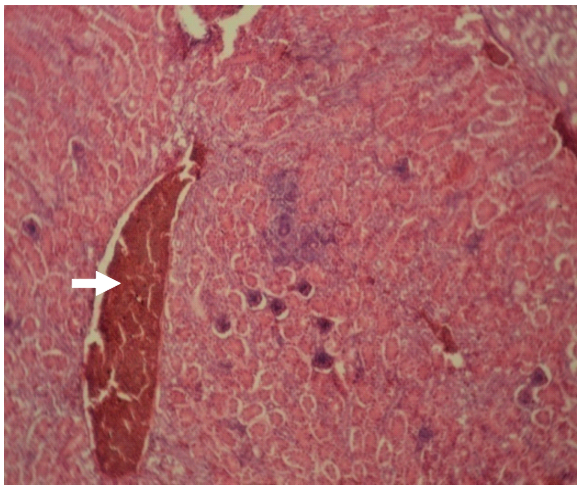

Fig. 5: Photomicrograph of kidney showing congestion (arrow), and toxic nephritic changes (H & E 10X).

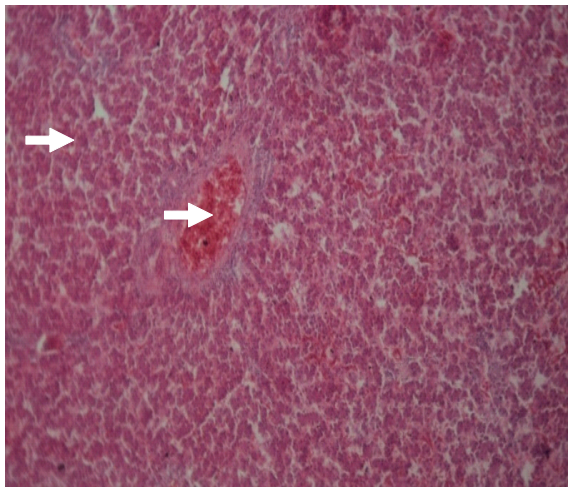

Fig. 6: Photomicrograph of liver showing vascular congestion, and hepatocellualar degeneration (arrow) (H & E 10X).

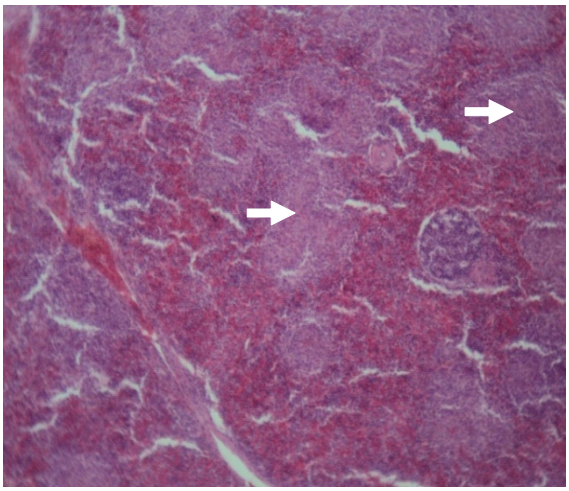

Fig. 7: Photomicrograph of spleen showing congestion, haemorrhages and depletion of lymphoid cells (arrow) (H & E 10X).

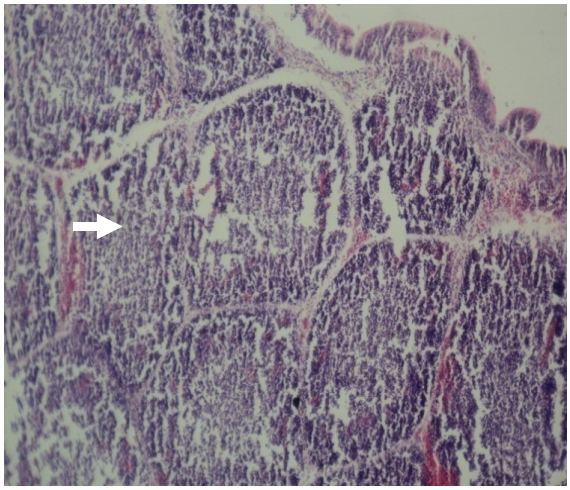

Fig. 8: Photomicrograph of bursa showing degeneration and washing out of lymphoid cells (arrow) (H & E 10X).

Intestine: Intestines revealed marked degeneration, necrosis and denudation of mucosa at the end of experimental period. Caecum of ziram intoxicated birds revealed desquamation of epithelial cells, submucosal oedema and necrosis (Fig. 12).

DISCUSSION

The use of pesticides, fungicides and fertilizers made the green revolution in India a success. Since the invention of pesticidal action of DDT, many pesticides and fungicides were evolved to control plant diseases, ectoparasites of domestic animals and to make the habitation free from mosquitoes. With the lapse of time it has been realized throughout the world, that these chemical pesticides and fungicides may be a source of toxicity to humans and animals. The danger posed by pesticides and fungicides resides in their residual effect. No chemical pesticide and herbicide is 100 per cent safe and hence, our ultimate goal should be to discontinue the practice of using chemical pesticides and fungicides either in the field or on animal body. This dream of mankind can be converted in to reality only when biological control of pests and insects becomes effective, economical and popular.

Carbamates are organic compounds derived from the

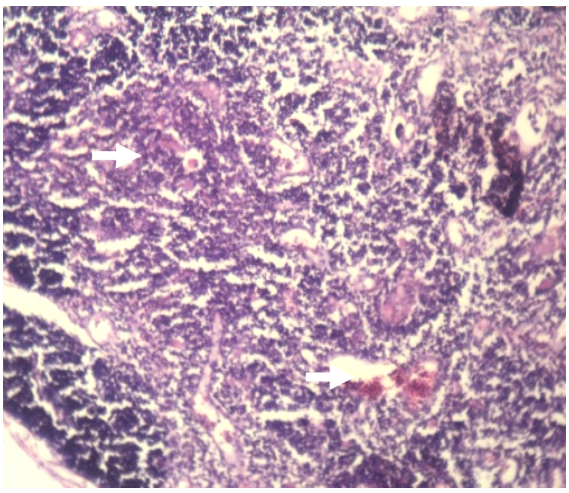

Fig. 9: Photomicrograph of thymus showing congestion and loss of lymphoid cells (arrow) (H & E 10X).

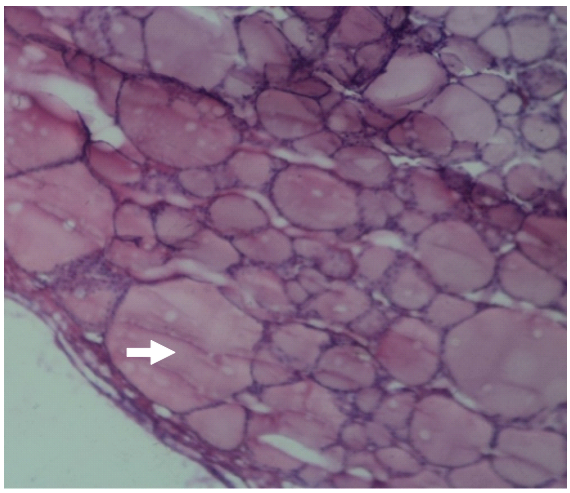

Fig. 10: Photomicrograph of thyroid showing hypertrophied follicles full of colloid material (arrow) and hyperplasia of glandular epithelium (H & E 10X).

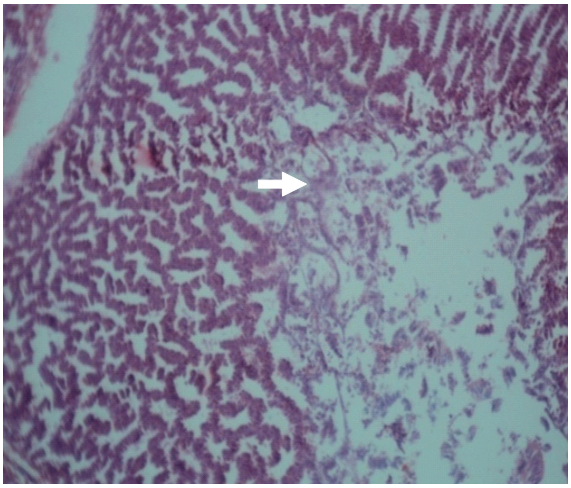

Fig. 11: Photomicrograph of proventriculus showing degeneration and denudation of mucosa (arrow) (H & E 10X).

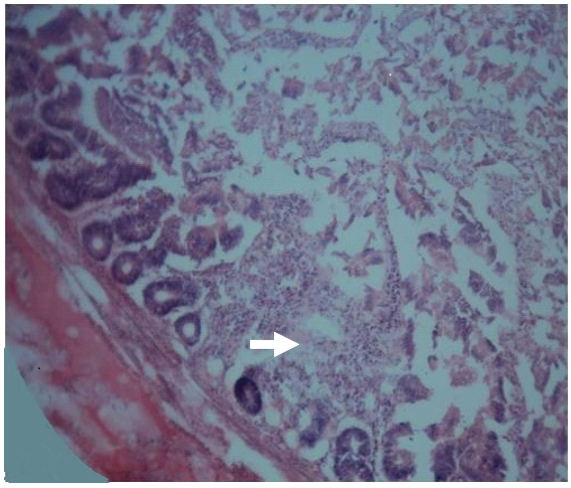

Fig. 12: Photomicrograph of caecum showing necrosis and denudation of mucosa (arrow) (H & E 10X).

carbonic acid. Ziram is used in agriculture to control fungal infections. It may also be used for seed treatment to improve the chances of germination. Ziram exposure may lead to the toxicity in birds as well as animals. Although wild birds potentially are exposed to field applications of the fungicide during their seasonal reproduction, there is little information on the effect of ziram in birds. The use of ziram has been reported recently in India as a fungicide, but little work has been carried out on any toxicity parameter. Dose of fungicide was selected on the basis of lethal dose of the fungicide in the birds.

In the present study, the ziram toxicity was experimentally induced following feeding of ziram in broiler feed. One group was kept as control in which no toxin was given. The dose rate and route selected in this study was such as to simulate the natural condition in which birds are exposed for the toxicity under field conditions.

Pathomorphological Observations

Brain: Marked vascular congestion was generally observed in brain on gross examination. Histopathologically, marked vascular congestion, neuronal degeneration, necrosis, satellitosis and neuronophagia were observed in the birds of toxicity groups. Similar changes have been reported by Ara

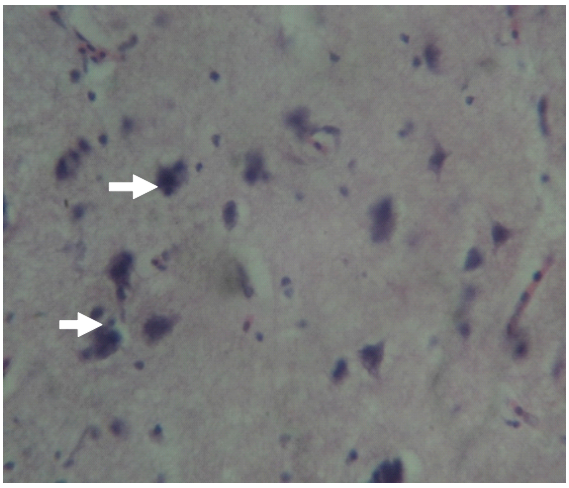

Fig. 13: Photomicrograph of brain showing neuronal degeneration (arrow), and satellitosis (arrow head) (H & E 40X).

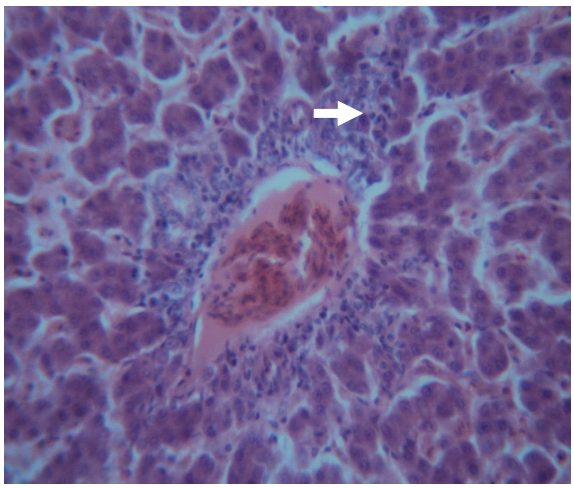

Fig. 14: Photomicrograph of liver showing vascular congestion, hepatocellular degeneration, and kuffer cell hyperplasia (arrow) (H & E 40X).

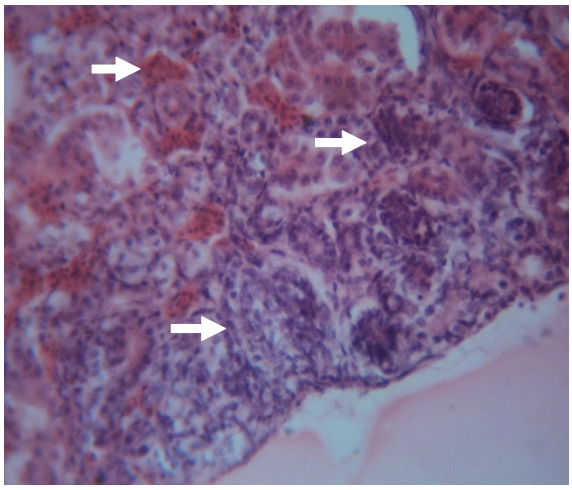

Fig. 15: Photomicrograph of kidney showing vascular congestion (arrow) and necrotic changes (arrow head) (H & E 40X).

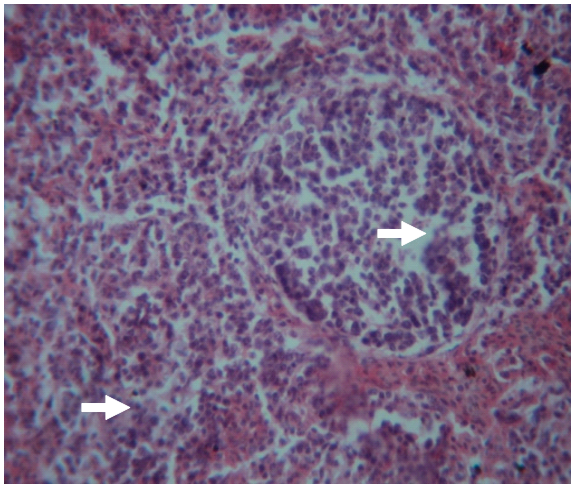

Fig. 16: Photomicrograph of spleen revealed loss of lymphoid cells (arrow) (H & E 40X).

et al. (2015) and Muthuviveganandavel et al. (2011) in cypermethrin toxicity of albino rats.

Lungs: Lungs appeared congested and heavy in the toxicity group on macroscopic examination. Histopathologically, the lesions of lungs included congestion, haemorrhages, focal areas of bronchopneumonia and emphysema in the birds of toxicity group. These lesions observed in the present study are in line with those observed by Sheikh et al. (1991) in mice and Maged et al. (2011) carbosulfan toxicity in male albino rats.

Heart: Generally, the heart appeared enlarged with increased quantity of pericardial fluid. Also petechiae haemorrhages were generally present on the epicardium. Microscopically, the lesions of heart revealed vascular congestion and Zenkers degeneration as observed by Gideon (1999) and Sabina et al. (2001) reported that carbaryl toxicity in rats.

Crop: The birds scarified at the day 90 showed severe degenerative changes and mucosal keratinization of crop as described earlier by Subapriya et al. (2007) in thiram toxicosis in broiler chicken.

Kidneys: The kidneys on gross examination appeared enlarged and congested with varying degrees of haemorrhages. Histopathologically, the kidneys of toxicity group revealed vascular congestion, cellular swelling, degeneration and

necrosis, which resembled with lesion observed in 60 weeks old white leghorn layers by Vardhani et al. (2014) and Maita (1999) in thiram toxicity in wistar rats and beagle dogs.

Liver: Grossly, the liver of all intoxicated birds revealed congestion with petechial haemorrhages on the surface. Microscopically, the birds sacrificed on the day 90th showed hepatic congestion, hepatocellular swelling and necrosis. Similar changes have been reported in cypermethrin toxicity in fishes by Neelima et al. (2015) and in albino rats by Mahajan et al. (2013) associated with carbaryl toxicity.

Spleen: Grossly, spleen revealed pinpoint necrotic spots with varying degrees of vascular congestion and haemorrhages in the birds of toxicity group. Microscopically, depletion of lymphoid cells was more prominent during later periods of the experiment. These changes in the spleen are in accordance with those reported by Karim et al. (2016) and Radad et al. (2009) in toxicity of in methomyl sprague-dawley rats.

Bursa: Haemorrhages and atrophy was more prominent in bursa of fabricius in sub chronic toxicity group which was easily visualized on gross examination. Histopathologically, bursa revealed vascular congestion, haemorrhages, interstitial oedema and depletion of lymphoid cells as reported earlier by Kumar et al. (2012) and Subapriya et al. (2007) in thiram toxicity of broiler chicks.

Thymus: Thymus in all intoxicated birds appeared to be reduced in size. Microscopically, haemorrhages with moderate depletion of lymphoid cells were consistently observed in all ziram intoxicated birds. These changes in the thymus are in accordance with those reported by Karim et al. (2016) and Dias et al. (2013) in thiodicarb toxicity of rats.

Thyroid: Slight increase in size of thyroid of sub chronic intoxicated birds was noted on macroscopic examination. Histopathologically, thyroid revealed vascular congestion, desquamation, haemorrhages, and hyperplasia of glandular epithelium. These lesions observed in the present study are in line with those observed by Lakshman et al. (2002) in thiram toxicity of broiler chick.

Proventriculus: Proventriculus was enlarged and oedematous with serous exudates in the lumen in ziram intoxicated birds. Histopathologically, vascular congestion, hyperplasia of mucosa and oedema of submucosa was a consistent feature in all ziram intoxicated birds as earlier reported by Ara et al. (2015) and Krishnamurthy et al. (2007) in chlorpyriphos toxicity chicken.

Gizzard: These lesions observed in the present study can be correlated with those observed by Anand et al. (2014) and Krishnamurthy et al. (2007) in chlorpyriphos on broiler chicken.

Intestine: Intestines and caecum revealed marked degeneration, necrosis and denudation of mucosa, which were more marked at the end of experimental period. Similar changes have also been observed by Gosselin et al. (1984) and Hayes et al. (1991) in ziram toxicity of rats.

On the basis of our results, it is clear that subchronic poisoning of birds with low doses of ziram has a toxic effect on liver, kidneys, thyroid and lymphatic organs. Thus, the presence of ziram in the environment, its possible ingestion by food and water, as well as accidental intoxication, could represent a risk to the human and livestock population.

REFERENCES

Ajaz 2010. How to minimize the use of pesticide and its effects in the farming system. www.greaterkashmir.com.

Ara, S., Pathak, D. and Goswami, S. 2015. Pathological changes of chlorpyriphos induced chronic toxicity in indigenous chicken. International Journal of Information Research, 5(2): 682-686.

Anand, T., Kumar, C. and Balachandran, C. 2014. Pathological effect of aflatoxin in broiler chicken. International Journal of Life Sciences and Pharm. Research, 4(4): 1-14.

Dias, E., Gomes, M. and Pereira, L. 2013. Subacute effects of the thiodicarb pesticide in Wistar rats. Journal of Toxicology and Environmental Health, 76(9): 533-539.

Gideon, H. 1999. The pathogenesis of Zenker'degeneration of striated muscles. Journal of Experimental Medicine, 11(1): 1-9.

Gosselin, R.E., Smith, R. and Hodge, C. 1984. Clinical Toxicology of Commercial Products. Williams and Wilkins, II: 314.

Hayes, J. and Laws, J. 1991. Handbook of Pesticide Toxicology, New York. Academic Press, pp. 1446.

Karim, A., Ahmad, N. and Wajid, A. 2016. Histopathological changes in spleen of silver carp after acute exposure to deltamethrin. Biologia., 62(1):139-144.

Krishnamurthy, P., Subbiah Vairamuthu, S. and Muralimanohar, B. 2007. Pathology of chlorpyriphos and T-2 toxin on broiler chicken. Veterlnarski Arhiv., 77(1): 47-57.

Kumar, N. and Singh, S. 2012. Pesticide toxicity in wild life with special reference to avian. International Journal of Toxicological and Pharmacological Research, 4(3): 49-56.

Lakshman, M., Ahemed, S.R. and Sarma, B.J.R. 2002. Effect of dietary tetra methyl thiuram disulphide (TMTD) on the development of experimental tibial dyschondroplasia (TD) in chicks. J. Vet. Pathol., 26: 43-45.

Lilly, R.D. 1954. Histological Technique and Practical Histochemistry. The Blakistan Div., McGraw Hills Book Company, Toranto.

Maged, A. 2011. Sub acute histopathological effects of carbosulfan in male albino rats. Egypt Journal Agriculture Research, 89(1): 177.

Maita, K., Tsuda, S. and Shirasu, Y. 1999. Chronic toxicity studies with thiram in wistar rats and beagle dogs. Fundamental and Applied Toxicology, 16(4): 667-86.

Mahajan, M., Hamid, S. and Singh, H. 2013. Histopathological effects of carbaryl in albino rats. Euroasian Journal of Heptogastroenterology, 3(1): 1-7.

Michael, A. and Kamrin, C. 1997. Toxicity of Pesticides and its Impact on Environment. Lewis Publishers CRC press, Boca Raton United States.

Muthuviveganandavel, V., Muthuraman, P. and Srikumar, K. 2011. Individual and combined biochemical andhistological effect of cypermethrin and carbendazimin male albino rats. Journal of

Applied Pharmaceutical Science, 1(9): 121-129.
Neelima, P., Kumar, A. and Rao, N. 2015. Histopathological alterations in gill, liver and kidney of fish exposed to cypermethrin. International Journal of Advanced Research in Biological Sciences, 2(2): 34-40.
Radad, K., Hashim, E. and Yousef, M. 2009. Histopathological effects of methomyl on sprague-dawley rats after repeated application. Bulgarian Journal of Veterinary Medicine., 12(2): 149-157.
Sheikh, N., Javed, S. and Iqbal, J. 2014. Histological changes in the lung and liver tissues in mice exposed to pyrethroid inhalation. Walailak Journal of Science & Technology, 11(10): 843-849.
Sabina, T. and Rodak, M. 2001. Histological and ultrastructural studies of rats exposed to Carbaryl. Annals of Agricultural and Environmental Medicine., 8: 137-144.
Subapriya, S., Vairamuthu, S., Manohar, B. and Balachandran, C. 2007. Pathomorphological changes in thiram toxicosis in broiler chicken. International Journal of Poultry Science, 6(4): 251-254.
Vardhani, V. and Meda, N. 2014. Imidacloprid induced histopathological alterations in the kidneys of male swiss albino mice. Indian Journal of Applied Research, 4(2): 23-25.